

# Special Senses

## Juvenile Cataracts in West Highland White Terriers

Lindsey Buracker, DVM  
and John Robertson, VMD, PhD

### Introduction

Dogs have a very keen sense of vision, with an ability to see in extreme conditions of light and darkness, and to be highly perceptive of movement. Although we generally don't think of them as primal predators, Westies are born with these instincts and need excellent vision. To make sense of what happens when cataracts develop, it is important to first have a solid understanding of the anatomy and physiology of the eye.

### The Anatomy of the Eye and the Phenomenon of Vision

The eye is comprised primarily of two connected chambers. The smaller of the two chambers, called the anterior chamber, is bounded by the transparent cornea at the front of the eye and the lens posteriorly. The larger posterior chamber, which is bounded externally by the tough outer layer called the sclera, contains the lens, the gelatinous vitreous humor, and the retina. The retina is a membrane comprised primarily of neural receptors that respond to light and initiate the visual pathway. The eye also contains blood vessels in the uveal tract and connective tissue.

The lens is an amazing tissue. It is a tight clustering of specialized cells, enclosed in a capsule, located behind the iris and in front of the vitreous body, held in place by fibers, the anterior vitreous face, and the iris (Magrane, 1972). The lens is normally quite flexible, and its shape is controlled by

small muscles and fibers that either tense or relax its edges. By changing its shape, the lens alters its refractive power to bring objects into focus, depending on whether they are near or far away. The lens grows in size with age, and requires nutrients that reach it by diffusion through the aqueous and vitreous humors. It also can be damaged by injury and disease, and has a limited ability to heal. Consequently, the shape of the lens changes during life.

There are three main components of the lens, namely the capsule, surface layer or epithelium, and fibers. The capsule is a thickened smooth membrane made of collagen and produced by the lens epithelium and fibers. It completely surrounds the lens and has elastic properties, so when not under tension, the lens assumes a rounded shape. The epithelium is comprised of cells that elongate over time and are eventually transformed into lens fibers, which contain high concentrations of the protein crystalline. It is this protein that helps the lens refract and transmit light. The fibers are tightly packed and extend the full length of the lens. Continual growth of the lens adds more elongated cells and fibers and produces an arrangement similar to the layers of an onion (Magrane, 1972). Damage to any of the components of the lens can result in a cataract.

The formation of the lens helps orchestrate the overall development of the eye, as it forms relatively early and helps induce the formation of both chambers and other parts of the eye. This pivotal role of the lens in controlling development of the eye is important for several reasons. First, if the lens does not properly form, this can affect the development of other parts of the eye. Second, disease or defective gene expression that occurs during pregnancy can significantly affect formation of the lens and, by extension, the development of healthy eyes. Third, the presence of

### Common Clinical Findings

Age When Recognized Varies

Autosomal Recessive Trait

Common Ancestors or Selective Breeding

Examination by Veterinary Ophthalmologist

cataracts at birth not only is indicative of abnormalities in lens development, but also may signal the potential for problems elsewhere in the eye. Finally, it is important to remember that puppies are born with incompletely matured eyes and some of the process of development takes place after birth. A good rule of thumb is that formation of the eye is complete by about 12 weeks of age, in most breeds of dog. Dogs should have good visual acuity by this age.

Vision is an interesting phenomenon. In essence, light energy from the surroundings produces electrochemical changes in specialized nerve cells called rods and cones in the retina. These changes result in the generation of signals called 'nerve action potentials' that are relayed to the brain, where they are processed and consciously appreciated as a vision (Magrane, 1972). The lens is a key part of the system that focuses and transmits light to the retina so that signals that eventually produce vision are received on the retina.

### An Introduction to Cataracts

Simply defined, a cataract is an irregularity and opacity in the lens. In most cases, the cataract appears as a cloudy white discoloration in the lens. It is important to know that cataracts can affect only one or both eyes. When cataracts develop in the center of the lens, they will interfere with the path of light to the retina at the back of the eye, which impairs visual acuity. Cataracts are classified as either 'immature' or 'mature,' terms that refer to the developmental stage of the cataract. Immature cataracts are newly formed and may occupy only a portion of the lens, whereas mature cataracts have been present longer and may involve the entire lens. In some mature cataracts, the cells in the lens have degenerated and liquefied. This debris persists within the lens capsule.

Many cataracts are more common in older dogs than young dogs, and develop in older dogs as a result of ocular disease (e.g., glaucoma, panophthalmitis and uveitis), systemic disease (e.g., diabetes mellitus), exposure to certain chemicals, as a side effect of radiation therapy of the head and neck, or direct penetrating trauma to the eye that damages the lens capsule and lens cells. These cataracts are considered to be "acquired" as a result of the initiating process.

Two specific ocular diseases associated with cataracts deserve specific mention: uveitis and glaucoma. Uveitis, an inflammation of the vascular ('uveal') layer of the eye, can be caused directly by degeneration of the lens, in some cases. With the formation and disruption of mature and hypermature cataracts, lens protein can leak from inside the lens capsule into the anterior chamber, spontaneously or as a result of trauma, and induce severe inflammation.

The relationship between glaucoma and cataract formation is complex. Glaucoma is a disease condition characterized by elevated intraocular pressure. In some cases of glaucoma, interference with the production and drainage of fluids within the eye is the primary disease process that increases intraocular pressure. The increased pressure within the eye may damage the lens, resulting in the formation of cataracts. In other cases, cataracts and other lens diseases may be a cause of glaucoma. For example, lenses with cataracts may become dislodged from their normal fibrous connections and migrate into the pupil, where they occlude the normal flow of fluid from the posterior chamber to the anterior chamber. This essentially blocks the drainage of fluid and pressure increases within the eye, resulting in glaucoma.

### Juvenile Cataracts

Cataracts also may form as the result of a defect during development of the eye. These cataracts, which are known as juvenile cataracts, either may form before birth or develop shortly after birth as the dog's eyes mature. Juvenile cataracts may be caused by the expression of defective genes and/or viral infections that occur during gestation or in newborns. In some breeds of dogs, the incidence of cataracts increases with age; these cataracts are considered to be hereditary in origin. Regardless of the cause, the outcome is the same – a decrease in visual acuity for the dog. Some inherited cataracts that appear early in the dog's life may result in blindness by the time the dog is 3 years of age. Other late onset inherited cataracts often do not interfere with vision and are identified before the dog reaches 8 years of age.

Most inherited cataracts in dogs are inherited as autosomal recessive traits, such as the mutation in heat shock transcription factor gene, HSF4, which is responsible for recessively inherited cataracts in Boston Terriers, Staffordshire Bull Terriers and French Bulldogs (Mellersh et. al., 2006). Typically, dogs are affected bilaterally, the cataracts are located in the posterior region of the lens, and the rate at which they grow is highly variable. Interestingly, Muller and coworkers (2008) were not able to identify mutations in HSF4 in Dachshunds or Entlebucher Mountain Dogs with hereditary cataracts.

Another mutation of the HSF4 gene affects Australian Shepherds, but is different from the mutation in Boston Terriers, French Bulldogs and Staffordshire Bull Terriers (Mellersh et. al., 2009). This mutation is dominant, meaning that only a single copy is needed to predispose a dog to the disease. Fortunately, not all dogs with this mutation develop cataracts, suggesting that one or more other gene interactions are involved in the process.

## “ Juvenile cataracts may form before birth or develop shortly after birth as the dog’s eyes mature.”

Many breeds of dogs appear to be predisposed to developing juvenile cataracts, including the West Highland White Terrier. To examine this concept, Oberbauer and colleagues recently compared the prevalence of ten inherited disorders, including early onset cataracts, in purebred and mixed breed dogs in a study of more than 88,000 dogs. They determined that the prevalence of early onset cataracts in most purebred groups was not different from that in mixed breed populations. They concluded that groups with higher specific disorders may have common ancestors or this could be an effect of selecting for specific structural features (e.g., shape or size).

Many puppies appear normal at birth, many do not show signs until six months to two years of age, and some may have the cataracts appear after five years. Consequently, there is no way to know if the puppy you are buying is going to develop juvenile cataracts. Fortunately, juvenile cataracts do not always lead to blindness. In many cases, the puppy or young

dog still sees basic shapes, but they may be blurry. In some cases, the disease leads to the development of glaucoma.

The only way to eradicate juvenile cataracts in dogs is for breeders to have both parents evaluated fully by a licensed veterinary ophthalmologist no more than a year before breeding. Because not all breeders do this, it is advisable to ask for eye registry papers for both parents before agreeing to purchase a puppy.

### Noticing Your Dog’s Eyes and Behavior

Owners and breeders are often the first to detect a problem with a dog’s eyes and vision. Some common signs that something is not right include:

- The eyes, lids, and membranes of the eye just don’t look right; there may be milky white/opaque discoloration, irregularities in shape and size, or perhaps the eyes are

**Table 8.1 Inherited cataracts in the dog (Gelatt, 2008)**

Breed	Age of Onset
Afghan Hound	6-12 Months
American Cocker Spaniel	6+ Months
Boston Terrier	Congenital
Chesapeake Bay Retriever	1+ Years
German Shepherd	8+ Weeks
Golden Retriever	6+ Months
Labrador Retriever	6+ Months
Miniature Schnauzer	Congenital or 6+ Months
Old English Sheepdog	Congenital
Siberian Husky	6+ Months
Staffordshire Bull Terrier	6+ Months
Standard Poodle	1+ Years
Welsh Springer Spaniel	Congenital
West Highland White Terrier	Congenital

inappropriately proportioned to the dog's head.

- Puppies may bump into things in their path, and observations that must be differentiated from just clumsiness or poor coordination).
- Puppies appear reluctant to move about or are overly shy; most Westie puppies are pretty affable and playful.
- Puppies are reluctant to explore darkened areas.
- Puppies appear to cue interactions based on hearing rather than on both hearing and seeing.

If a problem with vision is suspected, your dog's eyes should be examined by your veterinarian.

### Eye Examination by a Veterinarian

All thorough physical examinations of dogs include an evaluation of the eyes. Most evaluations by veterinarians include common elements, and some of the routine evaluation is done with simple tests:

- Evaluation of the gross appearance of both eyes, comparison of one eye with the other and with the head in terms of size, shape, coloration, tone, and integration with facial shape,
- Visual signal processing, based on the pupillary responses (constriction) to light shined in one eye. This is actually a simple test of a complex process, as it tests whether light focused on the retina then creates a visual 'signal' that is then transmitted via nerve fibers to the brain. At that point, the signal is interpreted as vision.
- The ability to track movement in a lighted area is assessed by the dog's responses to hand movements near the eyes. The veterinarian will determine if the dog will blink in response to movement near the eyes – assessing both visual perception and the automatic blink response.
- Tone (palpable firmness) of the eyes can be first evaluated by gently applying pressure through the lids. Most dogs do not mind this part of the examination and it helps determine if the eyes are firm, but not too firm, and if there are irregularities or pain,
- Ophthalmic evaluation of the anterior chamber, posterior chamber, and intraocular structures (lens, iris, pupil, retina).

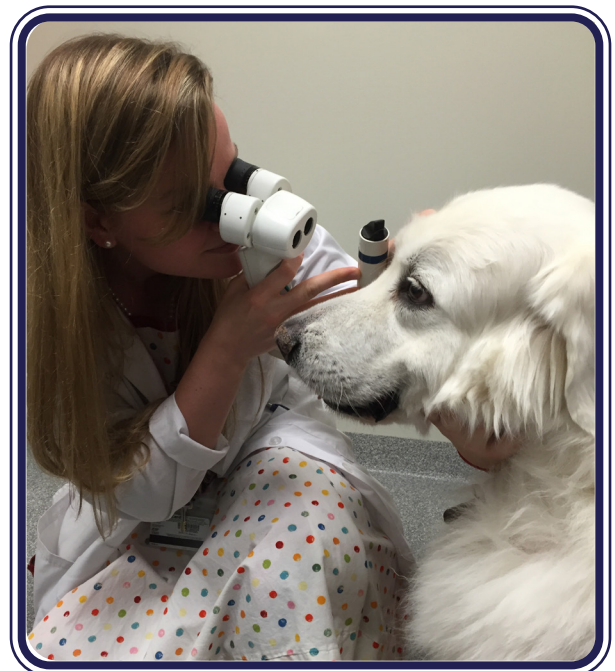
The value to Westie owners in seeking regular evaluations of their dogs should be evident. Health problems can be detected, diagnosed and most are treated effectively. Many eye problems can be detected with the above approach. When more complex treatments, such as surgery, are needed to treat problems and to correct defects, it makes sense to seek the services of a specialist, such as a veterinary ophthalmologist. These specialists have the facilities and

equipment needed for more extensive diagnostic approaches and for treatment (**Figure 8.1**). Because they concentrate exclusively on treating diseases of the eye, they have seen more cases, many of which are the more difficult ones, and will be more familiar with the variety of abnormalities affecting the lens (**Figures 8.2**). Veterinary ophthalmologists are certified by examination boards after years of advanced training and experience treating diseases of the eye.

### Prevention of Cataracts

Since we know that some types of cataracts have a hereditary basis (Table 1), it is essential for dog breeders to keep thorough records of litters and diseases affecting each pup. Breeders should keep in regular contact with the owners of pups from their litters throughout the lives of these dogs. The presence of cataracts in young dogs (less than 6 months old) and in multiple dogs from the same breeding is very suggestive of an underlying genetic problem. One caveat – if, during gestation, there is evidence of ill-health in the dam, cataracts may be the result of damage to the developing puppies. Most experienced breeders are very aware of the need to keep pregnant dams well-nourished and free from exposure to potentially damaging viruses and chemicals in the environment.

In the event that a litter is delivered and one or more pups develop cataracts, the breeder has a responsibility to 1) seek veterinary diagnosis and discuss treatment options for affected pups, 2) examine the breeding and pedigree of both dam and sire for similar problems (or the presence of



**Figure 8.1 - Examination of a dog's eyes using a specialized slit lamp ophthalmoscope.**

other congenital defects from this paired breeding), and 3) refrain from breeding either sire or dam until the relationship between breeding and cataract development can be clearly determined. Hereditary cataracts were first identified as a significant problem in the Miniature Schnauzer breed in the 1970s and 1980s. Following the leadership provided by breed associations, veterinarians and research scientists, this autosomal recessive trait was identified and bred against, resulting in a substantial decrease in the incidence of the disease in Miniature Schnauzers today. By identifying those dogs that are carriers of the disease and not breeding them, juvenile cataracts can be controlled and eventually eliminated. The importance of keeping accurate breeding records and long-term follow-up information on litters cannot be overstated.

Potential owners need to do an extensive “background check” before purchasing a Westie from a breeder. These potential Westie owners need to be sure there are accurate records for each dam and sire, a solid bloodline, and no overt problems or diseases noted in each litter from the time of whelping. If Westie owners and breeders work together, this disease will eventually be eliminated from breeding stock.

### Treatment

Before dogs with cataracts undergo surgical treatment, it is important to determine whether or not the dog is experiencing any vision problems. In other words, if the cataracts are relatively small and the dog is able to see sufficiently or can compensate for the impairment in vision, treatment isn’t needed. In some dogs, juvenile cataracts do not become more severe or do so very slowly. In other dogs, the severity of the cataracts may change and other problems, such as glaucoma and inflammation of the eye, may develop. Consequently, it is advisable to have the dog’s eyes checked on a regular basis. When cataracts interfere with vision, the dogs may have trouble finding their way in

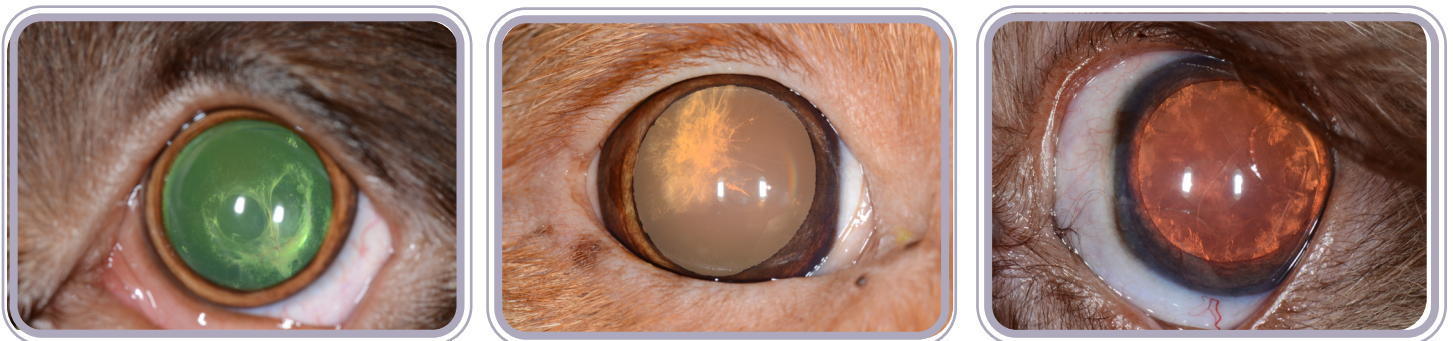their environment, locating food or water, and be reluctant to walk or run. In these cases, a visit to the veterinarian is warranted.

If cataracts are interfering with the dog’s vision, the treatment requires surgical intervention by a veterinary ophthalmologist. Before this is done, however, specialized tests including an ERG and ocular ultrasound will be performed to ensure that the dog’s retina is functioning normally. If the retina is not normal, the end result of surgery is not likely to be an improvement in visual acuity.

The most commonly used surgical technique involves using ultrasonic waves to transform the lens to a liquid, which then can be removed through a small incision. This technique, which is performed with the dog under general anesthesia, also is referred to as phacoemulsification. In many cases, an acrylic implant will be inserted to replace the lens that has been removed.

### Prognosis and Follow-up Care

Although there is a risk of complications with any surgery, the short-term prognosis for the return of visual acuity after surgery exceeds 90%. The long-term outcome regarding restored or improved vision ultimately depends on the stage of the cataract at the time surgery is performed and other co-existing conditions. A protective collar will be applied to prevent the dog from scratching the eye and initially frequent eye drops or lubricants will need to be administered. Typically, dogs that undergo surgery are examined 1 week after surgery, at which time additional long term follow-up examinations will be scheduled, since there remains a risk for complications.



Figures 8.2 - Example of the different ways that cataracts can appear in dogs.

## Current Research About Juvenile Cataracts in West Highland White Terriers

Jeon BJ, Lee SJ, Kim JL et al. Long-term evaluation of the effects of vitreous degeneration on cataracts and retinal detachment in dogs. *Vet Ophthalmol* 2023 Jul;26(4):324-330.

Data on vitreous degeneration, cataracts, and retinal detachment were collected from 68 dogs who underwent ocular ultrasonography at least twice between March 2017 and November 2021. The mean follow-up time was days. During long-term follow-up, dogs with severe vitreous degeneration had an increased risk of cataract and retinal detachment development than those without or with mild vitreous degeneration.

Lee E, Kang S, Jeong D, Seo K. Comparison of the outcomes of phacoemulsification versus topical medication alone in canine diabetic cataracts: a retrospective study. *J Vet Sci* 2023 Nov;24(6):e86.

This study was performed to compare the outcomes of dogs with diabetic cataracts treated with either phacoemulsification or topical medications and to identify risk factors for complications. Medical records of 150 eyes (76 dogs) with diabetic cataracts were included; 58 eyes (31 dogs) underwent phacoemulsification and 92 eyes (48 dogs) received ophthalmic solution alone. Comparisons involved time-to-complications, vision, and the number and type of ophthalmic solutions administered. Based on the results obtained, phacoemulsification is superior to topical management alone in terms of maintaining vision and reducing the number of ophthalmic solutions required in the long term.

Fischer MC, Meyer-Lindenberg A. Progression and complications of canine cataracts for different stages of development and aetiologies. *J Small Anim Pract* 2018 Aug 22.

This study was performed to evaluate progression and complications of various cataract aetiologies and stages of development. In all, 447 eyes of 250 dogs with cataracts were monitored between 2012 and 2015. Breed, gender, age, vision, types of cataract, stage of cataract development (incipient, immature, mature and hypermature), complications of cataracts, ocular ultrasonography and electroretinography findings were recorded. Complications were diagnosed in 43% and occurred at any stage but more frequently the further the cataract had developed. Lens-induced uveitis was the most common complication. Diabetic, traumatic, secondary and hereditary cataracts were associated with more complications than senile cataracts.

## Acknowledgements

Mr. Matthew Crotts, a medical illustrator in Educational Resources, created the illustrations used in this chapter, and Dr. Katie Diehl in the Department of Small Animal Medicine & Surgery provided the photographs. Both Mr. Crotts and Dr. Diehl are in the College of Veterinary Medicine at the University of Georgia.

## Relevant References

- Bellumori TP, Famula TR, Bannasch DL, Belanger JM, Oberbauer AM. Prevalence of inherited disorders among mixed-breed and purebred dogs: 27,254 cases (1995–2010). *J Am Vet Med Assoc*. 2013 Jun 1;242(11):1549–55.
- Brookshire HL, English RV, Nadelstein B, Weigt AK, Gift BW, Gilger BC. Efficacy of COX-2 inhibitors in controlling inflammation and capsular opacification after phacoemulsification cataract removal. *Vet Ophthalmol*. 2015 May;18(3):175–85.
- Crasta M, Clode AB, McMullen RJ Jr, Pate DO, Gilger BC. Effect of three treatment protocols on acute ocular hypertension after phacoemulsification and aspiration of cataracts in dogs. *Vet Ophthalmol*. 2010 Jan;13(1):14–9.
- Donzel E, Arti L, Chahory S. Epidemiology and clinical presentation of canine cataracts in France: a retrospective study of 404 cases. *Vet Ophthalmol*. 2016 Apr;17(1):1–9.
- Gelatt K. Diseases and surgery of the canine lens, in *Essentials of Veterinary Ophthalmology*, Wiley Blackwell Publishers, 2008.
- Gemensky-Metzler AJ, Sheahan JE, Rajala-Schultz PJ, Wilkie DA, Harrington J. Retrospective study of the prevalence of keratoconjunctivitis sicca in diabetic and nondiabetic dogs after phacoemulsification. *Vet Ophthalmol*. 2015 Nov;18(6):472–80.
- Gift BW, English RV, Nadelstein B, Weigt AK, Gilger BC. Comparison of capsular opacification and refractive status after placement of three different intraocular lens implants following phacoemulsification and aspiration of cataracts in dogs. *Vet Ophthalmol*. 2009 Jan-Feb;12(1):13–21.
- Klein HE, Krohne SG, Moore GE, Stiles J. Postoperative complications and visual outcomes of phacoemulsification in 103 dogs (179 eyes): 2006–2008. *Vet Ophthalmol*. 2011 Mar;14(2):114–20.
- Koll S, Reese S, Medugorac I, et al. The effect of repeated eye examinations and breeding advice on the prevalence and incidence of cataracts and progressive retinal atrophy in German dachshunds over a 13-year period. *Vet Ophthalmol*. 2016 Apr 13. [Epub ahead of print] PubMed PMID: 27073021.
- Krecny M, Tichy A, Rushton J, Nell B. A retrospective survey of ocular abnormalities in pugs: 130 cases. *J Small Anim Pract*. 2015 Feb;56(2):96–102.
- Lim CC, Bakker SC, Waldner CL, et al. Cataracts in 44 dogs (77 eyes): A comparison of outcomes for no treatment, topical medical management, or phacoemulsification with intraocular lens implantation. *Can Vet J*. 2011 Mar;52(3):283–8.
- Magrane, W, *Canine Ophthalmology*, 2nd ed. Lea and Febiger, Philadelphia, 1972
- Mellersh, CS, Pettitt L, Forman OP, et al. Identification of mutations in HSF4 in dogs of three different breeds with hereditary cataracts. *Vet Ophthalmol*. 2006;17(3):369–378.
- Mellersh CS, McLaughlin B, Ahonen S, et al. Mutation in HSF4 is associated with hereditary cataract in the Australian Shepherd. *Vet Ophthalmol*. 2009;12(6):372–378.
- Müller C, Wöhlke A, Distl O, "Evaluation of canine heat shock transcription factor 4 (HSF4) as a candidate gene for primary cataracts in the Dachshund and the Entlebucher Mountain dog," *Vet Ophthalmol*. 2008;11(1):34–37.
- Oberbauer AM, Belanger JM, Bellumori T, et al. Ten inherited disorders in purebred dogs by functional breed groupings. *Canine Genet Epidemiol*. 2015 Jul 11;2:9.
- Park SA, Yi NY, Jeong MB, Kim WT, Kim SE, Chae JM, Seo KM. Clinical manifestations of cataracts in small breed dogs. *Vet Ophthalmol*. 2009 Jul-Aug;12(4):205–10.
- Park YW, Kim JY, Jeong MB, Kim SH, Yoon J, Seo K. A Retrospective study on the association between vitreous degeneration and cataract in dogs. *Vet Ophthalmol*. 2015 Jul;18(4):304–8.
- Ricketts SL, Pettitt L, McLaughlin B, Jenkins CA, Mellersh CS. A novel locus on canine chromosome 13 is associated with cataract in the Australian Shepherd breed of domestic dog. *Mamm Genome*. 2015 Jun;26(5–6):257–63.