

Alternative Therapy for IPF

Michael Ina, DVM
Arguello Pet Hospital
San Francisco, CA 94118

On July 8, 2008, Kaylie, a ten and one half year old, spayed female Westie, was brought in for a routine teeth cleaning, 2 mass removals and chest radiographs. The owners wanted to have her lungs evaluated for pulmonary fibrosis. At this time, she was basically showing no symptoms. The radiographs were taken first because, if there was severe pulmonary disease, we were not going to use general anesthesia for the dentistry. I read the lungs out as having mild tracheal collapse and mild interstitial disease (pulmonary fibrosis).

Dr. Sam Silverman, a board certified veterinary radiologist, read Kaylie's radiographs.

Interpretation:

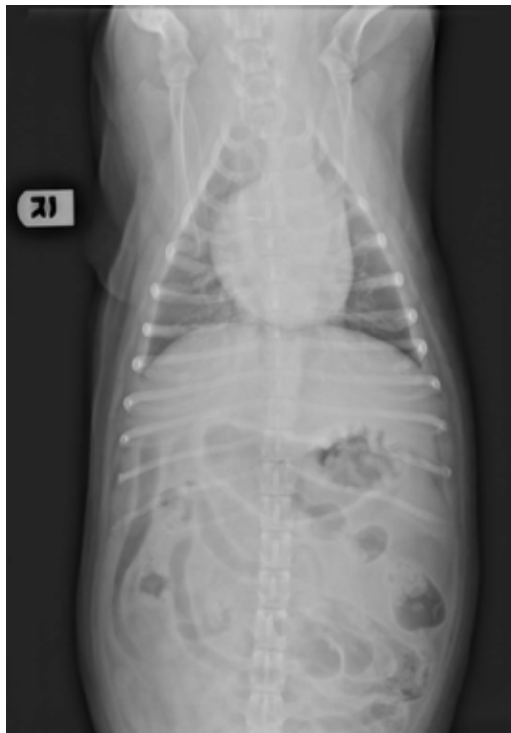The lungs are increased in opacity and are poorly inflated. The heart is at the upper limit of normal size. The diaphragm appears intact. Tracheal collapse may be present

Conclusion:

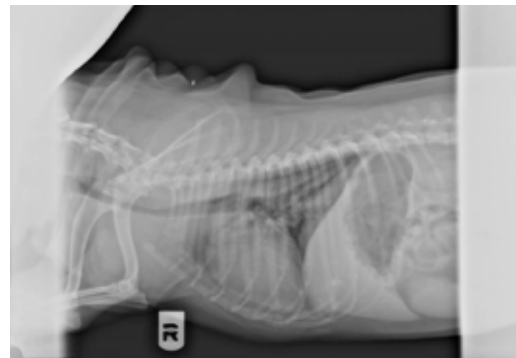
Interstitial pulmonary fibrosis (IPF) may be present.



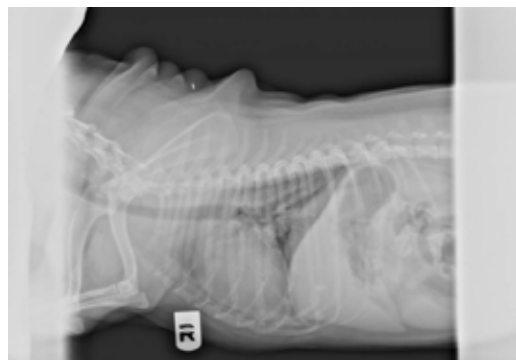Kaylie



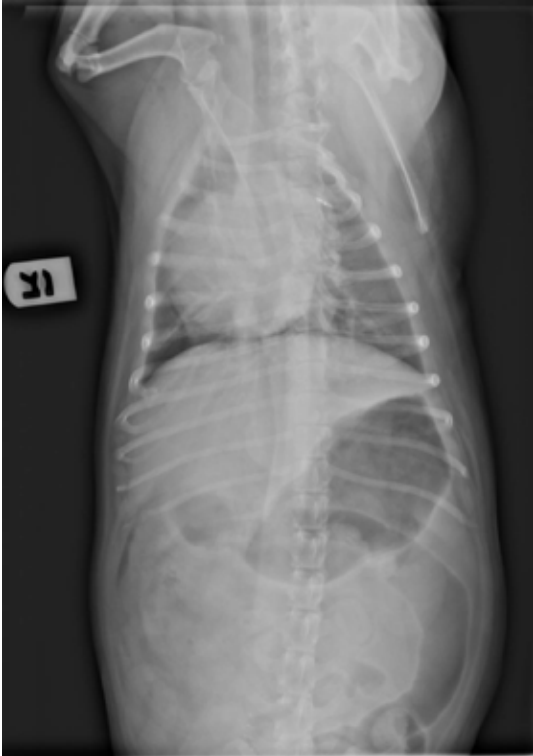
Kaylie - Radiograph #01 taken on 7-08-09, prior to treatment



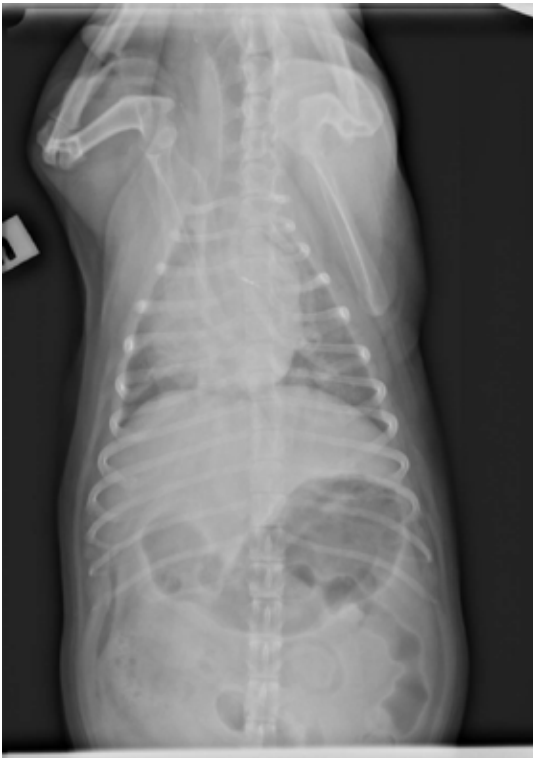Kaylie - Radiograph #02 taken on 7-08-09, prior to treatment



Kaylie - Radiograph #03 taken on 7-08-09, prior to treatment



Kaylie - Radiograph #06 taken 11-11-08 following initial treatment



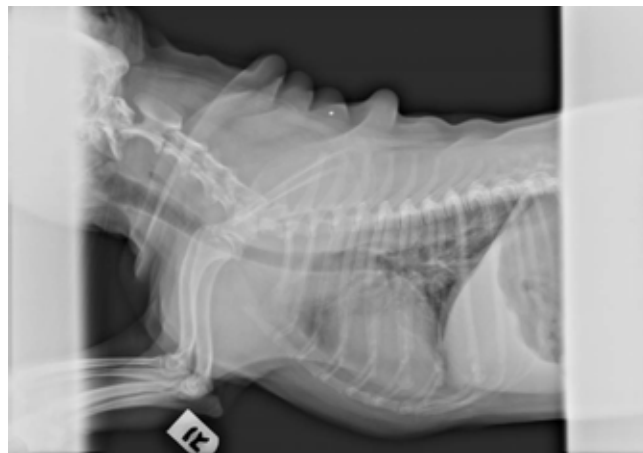
Kaylie - Radiograph #04 taken 11-11-08 following initial treatment

Mild tracheal collapse is also suspected. No evidence of heart failure.

On November 11, 2008, Kaylie was presented because of increased frequency of coughing, as much as 3 times a day. On physical exam, Kaylie's lungs were clear. Radiographs were taken (chemical restraint was not used).

Dr. Sam Silverman:

Interpretation: The cardiac silhouette is similar in size to the previous study. The radiographs were made at an incomplete phase of inspiration. No evidence of severe lobar consolidation or discrete pulmonary nodularity is seen. The tracheal caliber is mildly irregular. A large amount of gas is present in the stomach.



Kaylie - Radiograph #05 taken 11-11-08 following initial treatment

Conclusion: Changes are very similar to the previous study, differences in the phase of respiration and the lack of a complete inspiration at the time of radiographic exposure make it difficult to quantitate changes, however, persistent bronchointerstitial disease is likely.

We had tried bronchodilators to treat the collapsing trachea, but Kaylie could not tolerate Theophylline or Brethine.

I had purchased a cold laser unit in October 2008. It was delivered in November and I had studied how to use the



laser unit. The unit I purchased was the Companion Therapy Laser from LiteCure, LLC. It was a class IV laser therapy unit.

Kaylie's owner had informed me of a Westie in Carmel, California that was diagnosed with pulmonary fibrosis and was treated with cold laser. I contacted the veterinarian who treated this Westie and he informed me of his treatment protocol. Unfortunately, he never took radiographs after the laser therapy but he said he had treated the dog 6 times and the dog became asymptomatic (not coughing) for 4 weeks after the last treatment. He was in the process of starting a protocol of monthly follow up laser therapies.

The unit that the veterinarian from Watsonville used was an older unit than mine. I had called LiteCure about treating a Westie with IPF. The professional services returned my call with the recommendations for treating a dog with IPF.

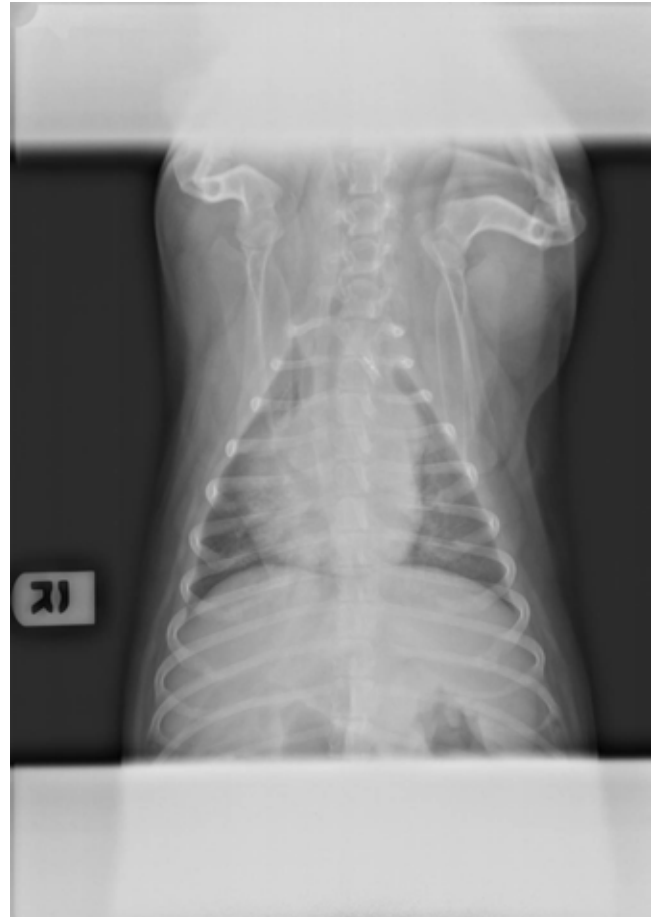On January 5, 2009, I started treating Kaylie with the cold laser unit. She was treated three times the first week, two times the second week and once the third. She received a total of six treatments. Kaylie's owner had told me that she thought Kaylie felt better after each session because she coughed less and was more active.

On February 17, 2009, we took radiographs to compare the lungs after the laser therapy.

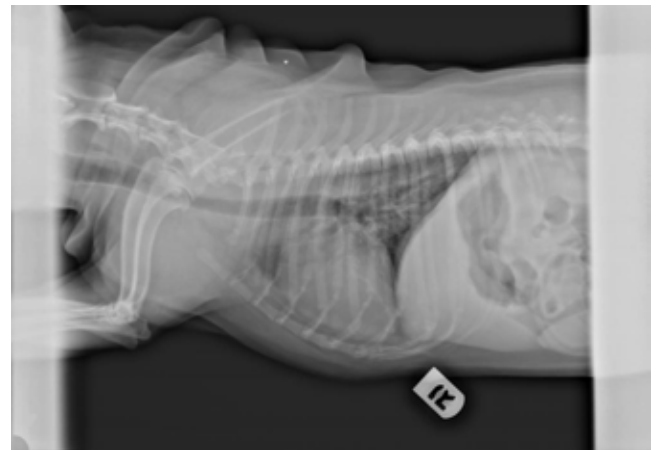
Dr. Sam Silverman:

Interpretation: Although the lungs are not completely inflated, they do appear somewhat more lucent on today's study. The bronchovascular markings remain indistinct but are improved in appearance. No evidence of free pleural fluid.

Conclusion: There appears to be an improvement in the appearance of the lungs compared to the previous study.



Kaylie - radiograph #07, taken on 2-17-09



Kaylie - radiograph #08, taken on 2-17-09

(A side note about the radiographs – it would have been better to sedate Kaylie when the radiographs were taken. She may have taken deeper breaths with sedation. However, because of her pulmonary disease, I was not willing to take unnecessary risks for the sake of possibly getting better radiographs).

Since February 23, 2009, Kaylie has been brought in once a month for a “tune-up” laser treatment. I listen to her lungs and get a history. The coughing ultimately did worsen. On

May 6, 2009 we tried albuterol solution via a child’s nebulizer. We have since added Flovent and discontinued the albuterol. Then on May 28, 2009 we added sildentafile.

It seems that high humidity and hot temperatures exasperated the coughing. On these uncomfortable days, the owner would minimize outdoor activities and try to keep Kaylie as cool as possible. Because of the possibility that inhalant irritants (house dust) could also exasperate the cough, Kaylie’s

owners now use the Dyson vacuum cleaner.

The owners continue to bring Kaylie in for her monthly laser treatment. Kaylie’s owner had noticed that for twenty four hours after these tune-up laser treatments, Kaylie seems to be much more active than usual. Ultimately, due to the owner’s dedication towards Kaylie, the addition of the drugs (Flovent and sildentafile) and the laser therapy, Kaylie has been able to maintain minimal coughing and a very good quality of life.



AMAZON.COM FOR WESTIES

Do you ever shop online at Amazon.com, the world’s largest online retailer, offering everything from books, music, movies, computers and televisions to groceries, health & beauty, sports and pet supplies? If you do or want to try something new, carefully follow the directions below:

- Go to the Westie Foundation website first (www.westiefoundation.org),
- Click on the Amazon.com banner at the top of the page (or the banner can also be found at the top of the “How to Help”, “Affiliates” and “Westie Gifts” pages),
- Wait for the link to take you to the Amazon.com website, and
- Place your order for any item you desire on Amazon.com.

The Westie Foundation will automatically receive at least 4% of your purchase price from Amazon.com. It doesn’t cost you a penny more; on the other hand you help pay for research and education to benefit the health and quality of life of Westies everywhere.

By the way, if you pay for your Amazon purchase with a Westie Foundation of America, Inc. MasterCard, the Foundation will receive money from both Amazon and Bank of America—two for one!

