

Digestive System

Inflammatory Bowel Disease (IBD)

By John Robertson, VMD, PhD

Westie Health E-Book

Inflammatory bowel disease is an immune related disorder in which the intestines are chronically or intermittently inflamed. A synonym for inflammatory bowel disease that is abbreviated the same way is ‘irritable bowel disease’. Affected dogs may be presented with a history of vomiting, diarrhea, weight loss or a combination of these signs. There is a great deal of variation in the severity, duration, response to therapy, and long-term effects of IBD among dogs.

While IBD exists in different forms, the most common is lymphocytic-plasmacytic enteritis (*Figure 1*), which means that the inflammation of the small intestine (*enteritis*) is associated with increased numbers of two white blood types that are linked to the immune system (*i.e.*, *lymphocytes and plasma cells*). These are the primary immune cell types that are identified in biopsies of the affected sections of the small intestine. Lymphocytes are the cells that detect and kill viruses, fungi, and even tumor cells. When they are exposed to infectious agents, including bacteria and some complex molecules like foreign proteins and complex carbohydrates, they can transform into cells that produce antibodies. These cells are called plasma cells. Lymphocytes also interact with other immune and inflammatory cells to create the body’s active defense system that helps protect people, dogs, and other animals against disease.

IBD also can affect other parts of the dog’s gastrointestinal tract. For example, the condition known as lymphocytic-plasmacytic colitis (*Figure 2*) primarily affects the colon (*a portion of the dog’s large intestine*). There also is a rare condition characterized by inflammation caused by a different type of white blood cell. This condition, called granulomatous enteritis/gastritis, affects the small intestines and/or stomach (*Figure 3*).

Canine IBD, especially granulomatous enteritis/gastritis, is similar in some respects to the human disorder, known as Crohn’s disease. Humans with Crohn’s disease experience many

of the same symptoms as dogs with IBD and are often treated in the same manner. In fact, much of our veterinary knowledge of IBD comes from research on Crohn’s disease using dogs and other animals with spontaneous and experimental disease as translational animal models. Because Crohn’s disease is thought to have a genetic component, veterinary researchers are examining the same possibility in dogs.

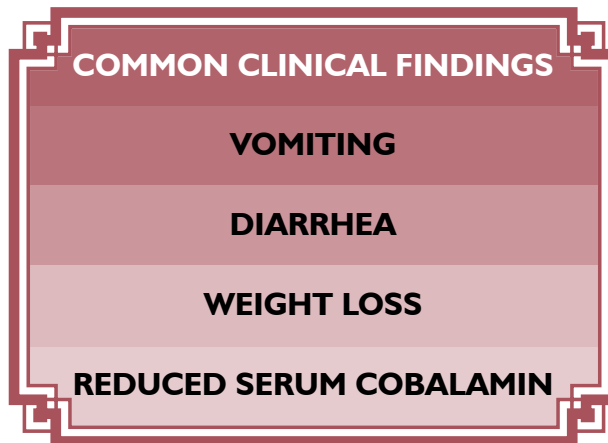
How Does A Dog Develop IBD?

Over the past few decades, several theories have been proposed regarding the cause of IBD. These include vascular

abnormalities that disrupt the function of the intestines, overproduction of mucus, an overactive gut, an infectious agent, or a dog with the equivalent of ‘hyperactivity disorder’. Currently, it is understood that IBD is an immune-related disorder, with strong evidence for a genetic predisposition in some breeds and alterations in the bacterial flora in the intestines, otherwise known as the microbiome. For example, single nucleotide polymorphisms have been identified in genes that encode for specific innate immune factors in German Shepherds

(*Allenspach et al, 2010*). There also is evidence for a shift in the bacterial populations in dogs with intestinal inflammation from gram-positive to gram-negative organisms, although at this point it is unknown if these changes are the cause or the result of the inflammation.

In a healthy dog, the small and large intestines, which includes the colon, have their own local part of the immune system. This purpose of the immune system in the gastrointestinal tract is to protect the body against viruses, bacteria or other antigens (*unwelcome outsider proteins and complex molecules*) that may be consumed in the dog’s food and water. The healthy intestinal tract is inhabited by a wide range of bacteria, many of which are important for the health of the dog. These ‘resident’ bacteria, otherwise known as normal flora, help restrict the other microbes and antigens to the lumen of the intestine; in essence,



(Continued on page 5)

the resident bacteria serve as a barrier against the unwanted microbes and antigens from gaining access to the circulation. Under normal circumstances, the intestinal immune system ignores the resident bacteria, allowing them to do their job.

However, in animals with IBD, a problem has developed in one of three areas: the local intestinal immune system or its regulation (*the body may be attacking itself or the resident bacteria*), the integrity of the intestines themselves (*through some type of injury*), or the balance of normal flora in the intestines has been disrupted. Any of these problems can trigger an unwanted immune response that becomes excessive and self-perpetuating.

What Are The Clinical Signs Associated With IBD?

The most prominent clinical signs in IBD are vomiting, diarrhea and weight loss. In general, dogs in which the small intestine is affected have large volume diarrhea, vomiting and weight loss, whereas those with involvement of the large intestine are constipated, strain or frequently defecate small amounts of feces containing blood and mucus. Often the clinical signs seem to come and go randomly, particularly in the early stages of the disease. During that time, affected dogs may appear perfectly healthy except for a change in stool consistency and frequency. A common effect of gastrointestinal inflammation is failure to absorb cobalamin (*vitamin B12*), a vitamin that has an important role in many biochemical reactions. Consequently, serum concentrations of cobalamin often are used to characterize the severity of the disease process. As cobalamin is absorbed in a specific segment of the small intestine, abnormal serum concentrations of cobalamin also help to localize the disease.

If the disease is undiagnosed or left untreated, some dogs may lose weight, and develop vitamin and mineral deficiencies that manifest as malnutrition. Another long-term problem that can occur is lymphangiectasia (*dilation of lymphatic vessels*), which can eventually result in significant protein loss and the development of tissue masses in the affected area.

How Is IBD Diagnosed?

The diagnosis of IBD is made by eliminating other possible causes for the dog's clinical problems. Because similar clinical signs (*vomiting and diarrhea*) occur with intestinal parasites, food allergies, dietary changes, stresses associated with moving/traveling/boarding, and even changes in household occupants (*like the arrival of new babies*), these must be ruled out first using a battery of diagnostic tests. For example, a fecal test will be performed to help rule out the potential role of parasites, such as *Giardia*. Blood work will be performed, and may reveal an increased population of immune-related cells, indicating inflammation. Abdominal ultrasound and xrays, taken either with or without a concurrent barium enema, may provide information about the status of the intestine. While both approaches may reveal other abnormalities, neither is very helpful in making a diagnosis of IBD, but may reveal other problems.

An important diagnostic test used to diagnose IBD is a thorough examination of the intestines with a flexible videoendoscope. A videoendoscope is a long cable with a camera on one end and a viewing port on the other. The camera-end of the videoendoscope is passed into the dog's gastrointestinal tract to allow the veterinarian to view the tissue lining the inside of the intestine and to take

(Continued on page 6)

Lymphocytic-plasmacytic enteritis

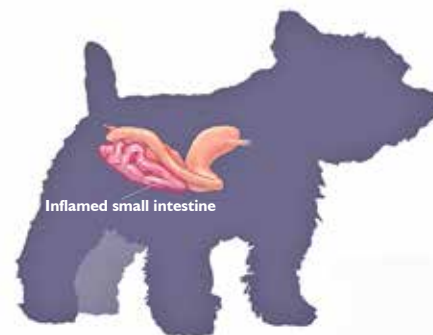

Figure 1 - The most common form of inflammatory bowel disease affects the small intestine (enteritis).

Lymphocytic-plasmacytic colitis

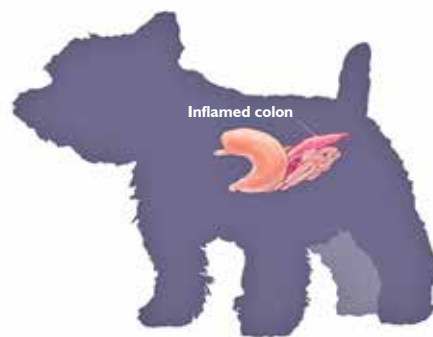

Figure 2 - This form of inflammatory bowel disease primarily affects the colon (colitis).

Granulomatous enteritis and gastritis

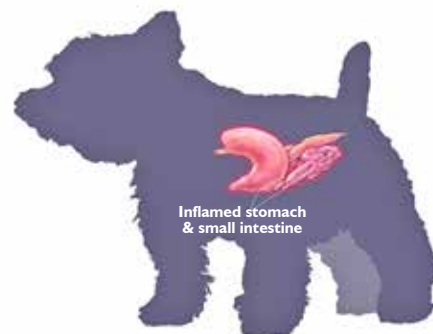

Figure 3 - This rare form of inflammatory bowel disease affects the small intestine and or stomach (enteritis and gastritis).



a biopsy, if necessary. In a 2015 study, Slovak and colleagues developed and prospectively validated an endoscopic scoring system for veterinarians to use to assess the severity of disease in dogs with IBD.

Having identified inflamed areas such as this, the veterinarian can obtain small samples of the tissue using a special biopsy instrument that is passed through the length of the videoendoscope and controlled from the outside. This procedure requires sedation, anesthesia, and is invasive, time-consuming and can be expensive. The biopsy samples are placed in a tissue fixative and prepared for microscopic examination by a veterinary pathologist, who will determine if they contain an excessive number of immune cells. It is important for the pathologist to have access to several biopsy specimens, as the inflammatory response either may be localized or diffuse. If the microscopic findings do not correlate with the dog's clinical signs and other findings, a full-thickness intestinal biopsy may be obtained during more invasive exploratory abdominal surgery. This approach allows the pathologist to more fully evaluate the intestine for changes in the small intestinal villi or mucus and goblet cells in the large intestine. For some affected dogs, this is the only way a definitive diagnosis of IBD can be made.

A major differential diagnosis in dogs with some of these signs is a specific cancer affecting the intestine called malignant lymphoma. Making this diagnosis requires collaboration

between the clinical veterinarian and a skilled pathologist, as the most common features of this neoplastic disease is the presence of an increased number of abnormal lymphocytes in the biopsy tissue. A major differentiating feature of IBD is the presence of mixed populations of normal lymphocytes, plasma cells, and sometimes cells like neutrophils and eosinophils (Craven, et al, 2004). If there is any doubt about the diagnosis, it is an excellent idea to obtain a second opinion from another veterinary pathologist.

A veterinarian may also use the canine IBD activity index to "score" a patient's clinical signs and determine the severity of the disease (Jergens 2004; Jergens et al, 2003, 2010). Using this approach, the veterinarian assigns a number from 1 to 3 for each of six clinical signs: attitude/activity, appetite, vomiting, stool consistency, stool frequency and weight loss. The total score is used to determine if the disease is considered clinically insignificant, mild, moderate or severe. This index is based on similar approaches designed to quantify Crohn's disease in humans and can be used to assess a patient's progress with treatment.

Although routine blood tests typically are not very helpful in making a definitive diagnosis of IBD, the low serum protein and cholesterol concentrations that typically are measured in dogs with IBD provide evidence of a protein-losing intestinal abnormality. While this is not a way to definitively diagnose IBD, this is certainly one of the major reasons routine bloodwork is performed in patients with chronic gastrointestinal signs. Other abnormalities that may be identified in a small number of dogs with IBD are decreased numbers of circulating platelets; this abnormality was present in 2.5% of affected dogs in one study (Ridgway, et al, 2001). Treatment of these dogs for IBD resolved the low platelet count. In another case report, two dogs were identified with anemia, presumably due to blood loss through the gastrointestinal tract (Ristic, et al, 2002).

Treatment Of IBD

Unfortunately, relatively little is known about the effectiveness of particular treatments for IBD. As a result, treatment is based on empirical evidence and the clinical experience of the veterinarian. Treatment of IBD is usually multifaceted and will likely include a combination of diet changes, antibiotics and immunosuppressive drugs, including the use of corticosteroids such as prednisone. Management of dogs with IBD using medications alone is not recommended and usually is of limited value.

DIETARY CHANGES: One of the most important components of treating a dog with IBD is to change the dog's diet. This can be done by switching to a completely different diet, to reduce exposure to certain antigens that might be present in the current

(Continued on page 7)

feed. Similarly, commercial diets may be fed that contain hydrolyzed proteins that are smaller than typical proteins so as not to be recognized as antigens. Many veterinarians recommend feeding a highly digestible, rice-based diet that contains readily digestible fats and restricted amounts of fiber. Other dietary changes that can be made include altering the relative levels of omega3 and omega6 fatty acids (*to reduce inflammation*), and feeding prebiotics, such as inulin, or probiotics, such as Lactobacillus. The positive results obtained in recent studies in which dietary modifications were made in dogs with lymphocytic-plasmacytic enteritis underscores the importance of restricting exposure to antigens; in those studies, more than 60% of dogs responded positively and many did not require prolonged treatment with immunosuppressive drugs (*Mandigers et al, 2010; Luckschander, et al, 2006*).

ANTIBIOTICS: Antibiotics are administered to dogs with IBD in the hopes of reducing the amount of bacterial antigens present in the intestinal lumen and to control any bacterial overgrowth that might exist. Regardless, the aim is to reduce the intestinal immune response and local inflammation that are associated with IBD. The most commonly used antibiotics are tylosin or metronidazole, which in addition to its antibacterial effects also may help modulate the immune response. The beneficial responses that occur in some dogs with antibiotic therapy strongly suggest that these animals have what is called antibiotic-responsive enteropathy.

IMMUNOSUPPRESSIVE DRUGS: Based on the apparent role played by the immune system in the development of IBD, corticosteroids are given to suppress this response. Unfortunately, administration of these drugs is associated with a variety of ill effects, including gastric ulcers, increased appetite, increased urination, obesity, muscle weakness, and development of diabetes. Consequently, veterinarians are interested in pharmacologic agents that modulate the immune system, but cause fewer side effects. Because similar problems occur in human IBD patients administered corticosteroids, a relatively new drug called budesonide has been developed which is as effective as another commonly used corticosteroid, prednisone. In a recent clinical study comparing budesonide and prednisone in 40 client-owned dogs, Dye et al (2013) reported that both drugs resulted in similar remission rates (>75%) but the frequency of adverse effects also was similar between the groups.

If the response to corticosteroid therapy is poor, many veterinarians also use

azathioprine, cyclosporine A, and/or mycophenolate mofetil, immunosuppressive drugs sometimes used to treat autoimmune diseases and cancer. The most common side effect of treatment with azathioprine is bone marrow suppression, whereas gastrointestinal side effects tend to occur with the use of cyclosporine A and mycophenolate mofetil. In one study, Allenspach and coworkers (2006) administered cyclosporine A to 14 dogs that had not responded well to corticosteroid therapy, and reported concurrent improvements in clinical signs in 12 dogs and a decrease in the number of lymphocytes in intestinal biopsies obtained from these animals.

COBALAMIN SUPPLEMENTATION: Human patients with chronic gastrointestinal diseases often require monthly injections of vitamin B12 to address the low circulating concentrations of this vitamin, and a similar situation exists in dogs with chronic enteritis, such as IBD. In a 2016 study, Toresson and colleagues studied 51 dogs with chronic enteritis and low serum cobalamin concentrations, and reported that oral administration of cobalamin effectively normalized the concentrations. While these results are promising, the authors suggested that more in-depth studies need to be performed before oral supplementation can be recommended as part of the routine treatment for affected dogs.

It is critical for owners of dogs with IBD to realize that managing this disease requires a lifelong commitment. The prognosis for a dog with IBD depends on the severity of the disease and the progression at the time of diagnosis. While a change in diet and close monitoring of the dog may be all that's needed to manage many affected dogs, for others the situation may be quite different. Therefore, it is important for owners to be aware that this is a disease that is unable to be cured, instead it can be managed long-term, with the goal of achieving remission.



(Continued on page 8)

Current Research About Inflammatory Bowel Disease

Because IBD occurs in a variety of breeds, including Yorkshire and Soft Coated Wheaten Terriers, the disease may be of increased interest to Westie owners. In this section, we summarize the results of two recent studies about this important disease.

Pérez-Merino EM, Usón-Casaús, JM, Zaragoza-Bayle C, et al. *Safety and efficacy of allogeneic adipose tissue-derived mesenchymal stem cells for treatment of dogs with inflammatory bowel disease: Clinical and laboratory outcomes.* The Vet J 2015. 206:385-390.

There is a lot of interest in using stem cells in the treatment of different diseases. One of the reasons for considering them as a possible treatment for IBD is that stem cells have been shown to exert anti-inflammatory and immune system modulatory effects in different studies. In this study, adult stem cells called derived from adipose tissue were tested for their safety and feasibility of use in 11 dogs with IBD. The dogs were administered the stem cells IV and their responses were summarized 6 weeks later. None of the dogs reacted adversely to the stem cells, and there was evidence of clinical improvement in 9 of the 11 dogs, including an increase in serum cobalamin. The investigators concluded that the stem cells were well tolerated and appeared to produce clinical benefits with severe IBD.

Rossi G, Pengo G, Caldin M, et al. *Comparison of microbiological, histological, and immunomodulatory parameters in response to treatment with either combination therapy with prednisone and metronidazole or probiotic VSL#3 strains in dogs with idiopathic inflammatory bowel disease.* PLoS One 9(4): 1-13, 2014.

Based on the alterations in the bacterial populations that exist in the gastrointestinal tracts of dogs with IBD, there is a lot of interest in the potential use of probiotics in the treatment of dogs affected with this disease. This study was performed to compare the responses of dogs with IBD to treatment with either a commonly used combination therapy (*prednisone and metronidazole*) or probiotic strains (*VSL#3*). In this study, 20 dogs with IBD were randomly assigned to each treatment group and then monitored for 2 months during treatment and 1 month later. The dogs receiving the probiotic had improved clinical scores and reduced evidence of lymphocyte infiltration into the intestine when compared to the dogs receiving the combination therapy. This initial study provides the bases for larger clinical trials to evaluate the effectiveness of VSL#3 in dogs with IBD.



Acknowledgements

Mr. Matthew Crotts, a medical illustrator in Educational Resources in the College of Veterinary Medicine at the University of Georgia, created the illustrations used in this chapter.

Relevant References

- Allenspach K, House A, Smith K. Evaluation of mucosal bacteria and histopathology, clinical disease activity and expression of Toll-like receptors in German Shepherd dogs with chronic enteropathies. *Vet Microbiol* 2010; 146(3-4): 326-335.
- Allenspach K, Rüfenacht S, Sauter S, Gröne A, Steffan J, Strehlau G, Gaschen F. Pharmacokinetics and clinical efficacy of cyclosporine treatment of dogs with steroidrefractory inflammatory bowel disease. *J Vet Intern Med* 20(2):239-44, 2006.
- Allenspach K, Steiner JM, Shah BN, Berghoff N, Ruaux C, Williams DA, Blum JW, Gaschen F. Evaluation of gastrointestinal permeability and mucosal absorptive capacity in dogs with chronic enteropathy. *Am J Vet Res* 67(3):479-83, 2006.
- Cassmann E, White R, Atherly T, Wang C, Sun Y, Khoda S, Mosher C, Ackermann M, Jergens A. Alterations of the Ileal and Colonic Mucosal Microbiota in Canine Chronic Enteropathies. *PLoS One*. 2016 Feb 3;11(2):e0147321.
- Cave NJ. Hydrolyzed protein diets for dogs and cats. *Vet Clin North America: Small Animal* 36(6):125-168, 2006.
- Craven M, Simpson JW, Ridyad AE, Chandler ML. Canine inflammatory bowel disease: retrospective analysis of diagnosis and outcome in 80 cases (1995-2002). *J Small Anim Pract* 45(7):336-42, 2004.
- Cerquetella M, Spaterna A, Laus F, Tesi B, Rossi G, Antonelli E, Villanacci V, Bassotti G. Inflammatory bowel disease in the dog: differences and similarities with humans. *World J Gastroenterol*. 2010 Mar 7;16(9):1050-6.
- Collins MT. Canine inflammatory bowel disease: current and prospective biomarkers for diagnosis and management. *Compend Contin Educ Vet*. 2013 Mar;35(3):E5.

(Continued on page 9)

- Dye TL, Diehl KJ, Wheeler SL, Westfall DS. Randomized, controlled trial of budesonide and prednisone for the treatment of idiopathic inflammatory bowel disease in dogs. *J Vet Intern Med.* 2013 Nov-Dec;27(6):1385-91.
- Foster AP, Knowles TG, Moore AH, Cousins PD, Day MJ, Hall EJ. Serum IgE and IgG responses to food antigens in normal and atopic dogs, and dogs with gastrointestinal disease. *Vet Immunol and Immunop* 92(34):113-24, 2003.
- Heilmann RM, Suchodolski JS. Is inflammatory bowel disease in dogs and cats associated with a Th1 or Th2 polarization? *Vet Immunol Immunopathol.* 2015 Dec 15;168(3-4):131-4.
- Jergens AE, "Clinical assessment of disease activity for canine inflammatory bowel disease" *Journal of the American Animal Hospital Association:* 40(6):43745, 2004
- Jergens AE, Schreiner CA, Frank DE, Niyo Y, Ahrens FE, Eckersall PD, Benson TJ, Evans R, "A scoring index for disease activity in canine inflammatory bowel disease" *J Vet Intern Med* 17(3):2917, 2003
- Jergens AE, Crandell J, Morrison JA, Deitz K, Pressel M, Ackermann M, Suchodolski JS, Steiner JM, Evans R. Comparison of oral prednisone and prednisone combined with metronidazole for induction therapy of canine inflammatory bowel disease: a randomized-controlled trial. *J Vet Intern Med.* 2010;24(2):269-77.
- Luckschander N, Allenspach K, Hall J, Seibold F, Gröne A, Doherr MG, Gaschen F, "Perinuclear antineutrophilic cytoplasmic antibody and response to treatment in diarrheic dogs with food responsive disease or inflammatory bowel disease" *J Vet Intern Med* 20(2):221-7, 2006.
- Maeda S, Ohno K, Fujiwara-Igarashi A, Uchida K, Tsujimoto H. Changes in Foxp3-Positive Regulatory T Cell Number in the Intestine of Dogs With Idiopathic Inflammatory Bowel Disease and Intestinal Lymphoma. *Vet Pathol.* 2016 Jan;53(1):102-12.
- Maeda S, Ohno K, Nakamura K, Uchida K, Nakashima K, Fukushima K, Tsukamoto A, Goto-Koshino Y, Fujino Y, Tsujimoto H. Mucosal imbalance of interleukin-1 β and interleukin-1 receptor antagonist in canine inflammatory bowel disease. *Vet J.* 2012 Oct;194(1):66-70.
- Maeda S, Ohno K, Uchida K, Nakashima K, Fukushima K, Tsukamoto A, Nakajima M, Fujino Y, Tsujimoto H. Decreased immunoglobulin A concentrations in feces, duodenum, and peripheral blood mononuclear cells of dogs with inflammatory bowel disease. *J Vet Intern Med.* 2013 Jan-Feb;27(1):47-55.
- Mandigers PJ, Biourge V, Van Den Ingh TS. A randomized, open-label, positively controlled field trial of a hydrolyzed protein diet in dogs with chronic small bowel enteropathy. 2010; 24(6): 1350-11357.
- Minamoto Y, Otoni CC, Steelman SM, Büyükleblebici O, Steiner JM, Jergens AE, Suchodolski JS. Alteration of the fecal microbiota and serum metabolite profiles in dogs with idiopathic inflammatory bowel disease. *Gut Microbes.* 2015;6(1):33-47. *Digestive System / 77*
- Nakashima K, Hiyoshi S, Ohno K, Uchida K, Goto-Koshino Y, Maeda S, Mizutani N, Takeuchi A, Tsujimoto H. Prognostic factors in dogs with protein-losing enteropathy. *Vet J.* 2015 Jul;205(1):28-32.
- Ohta H, Sunden Y, Yokoyama N, Osuga T, Lim SY, Tamura Y, Morishita K, Nakamura K, Yamasaki M, Takiguchi M. Expression of apical junction complex proteins in duodenal mucosa of dogs with inflammatory bowel disease. *Am J Vet Res.* 2014 Aug;75(8):746-51.
- Pérez-Merino EM, Usón-Casaús JM, Zaragoza-Bayle C, Duque-Carrasco J, Mariñas-Pardo L, Hermida-Prieto M, Barrera-Chacón R, Gualtieri M. Safety and efficacy of allogeneic adipose tissue-derived mesenchymal stem cells for treatment of dogs with inflammatory bowel disease: Clinical and laboratory outcomes. *Vet J.* 2015 Dec;206(3):385-90.
- Pérez-Merino EM, Usón-Casaús JM, Duque-Carrasco J, Zaragoza-Bayle C, Mariñas-Pardo L, Hermida-Prieto M, Vilafranca-Compte M, Barrera-Chacón R, Gualtieri M. Safety and efficacy of allogeneic adipose tissue-derived mesenchymal stem cells for treatment of dogs with inflammatory bowel disease: Endoscopic and histological outcomes. *Vet J.* 2015 Dec;206(3):391-7.
- Ridgway J, Jergens AE, Niyo Y, "Possible causal association of idiopathic inflammatory bowel disease with thrombocytopenia in the dog" *Journal of the American Animal Hospital Association:* 37(1):6574, 2001.
- Ristic JM, Stidworthy MF, "Two cases of severe iron deficiency anaemia due to inflammatory bowel disease in the dog" *The Journal of Small Animal Practice:* 43(2):803, 2002.
- Rossi G, Pengo G, Caldin M, Palumbo Piccionello A, Steiner JM, Cohen ND, Jergens AE, Suchodolski JS. Comparison of microbiological, histological, and immunomodulatory parameters in response to treatment with either combination therapy with prednisone and metronidazole or probiotic VSL#3 strains in dogs with idiopathic inflammatory bowel disease. *PLoS One.* 2014 Apr 10;9(4):e94699.
- Rudorf H, van Schaik G, O'Brien RT, Brown PJ, Barr FJ, Hall EJ, "Ultrasonographic evaluation of the thickness of the small intestinal wall in dogs with inflammatory bowel disease" *J Small Anim Pract* 46(7):322-6, 2005.
- Rychlik A, Nieradka R, Kander M, Nowicki M, Wdowiak M, Kołodziejska-Sawerska A. The effectiveness of natural and synthetic immunomodulators in the treatment of inflammatory bowel disease in dogs. *Acta Vet Hung.* 2013 Sep;61(3):297-308.
- Schmitz S, Garden OA, Werling D, Allenspach K. Gene expression of selected signature cytokines of T cell subsets in duodenal tissues of dogs with and without inflammatory bowel disease. *Vet Immunol Immunopathol.* 2012 Mar 15;146(1):87-91.
- Simpson KW, Jergens AE. Pitfalls and progress in the diagnosis and management of canine inflammatory bowel disease. *Vet Clin Small Anim* 2011 41:381-398.
- Slovak JE, Wang C, Sun Y, Otoni C, Morrison J, Deitz K, LeVine D, Jergens AE. Development and validation of an endoscopic activity score for canine inflammatory bowel disease. *Vet J.* 2015 Mar;203(3):290-5.
- Slovak JE, Wang C, Morrison JA, Deitz KL, LeVine DN, Otoni C, King RR, Gerber LE, Hanson KR, Lundberg AP, Jergens AE. Endoscopic assessment of the duodenum in dogs with inflammatory bowel disease. *J Vet Intern Med.* 2014 Sep-Oct;28(5):1442-6.
- Suchodolski JS, Markel ME, Garcia-Mazcorro JF, Unterer S, Heilmann RM, Dowd SE, Kachroo P, Ivanov I, Minamoto Y, Dillman EM, Steiner JM, Cook AK, Toresson L. The fecal microbiome in dogs with acute diarrhea and idiopathic inflammatory bowel disease. *PLoS One.* 2012;7(12):e51907.
- Titmarsh H, Gow AG, Kilpatrick S, Sinclair J, Hill T, Milne E, Philbey A, Berry J, Handel I, Mellanby RJ. Association of Vitamin D Status and Clinical Outcome in Dogs with a Chronic Enteropathy. *J Vet Intern Med.* 2015 Nov-Dec;29(6):1473-8.
- Toresson L, Steiner JM, Suchodolski JS, Spillmann T. Oral Cobalamin Supplementation in Dogs with Chronic Enteropathies and Hypocobalaminemia. *J Vet Intern Med.* 2016 Jan;30(1):101-7.
- Tumulty JW, Broussard JD, Steiner JM, Peterson ME, Williams DA, "Clinical effects of short-term oral budesonide on the hypothalamic-pituitary-adrenal axis in dogs with inflammatory bowel disease" *Journal of the American Animal Hospital Association:* 40(2):120-3, 2004.
- Zoran D, "Nutritional management of gastrointestinal disease" *Clinical Techniques in Small Animal Practice:* (4):2117, 2003.