

Canine Bladder Cancer

By Deborah W. Knapp, DVM, Dipl. ACVIM

Reprinted from Purdue University website at vet.purdue.edu/pcop/urinary-bladder-cancer-research.php

Cancer of the urinary tract in dogs can affect the kidneys, ureters, urinary bladder, prostate, or urethra (see Figure 1). Within the urinary system, the bladder is the location most frequently affected with cancer.



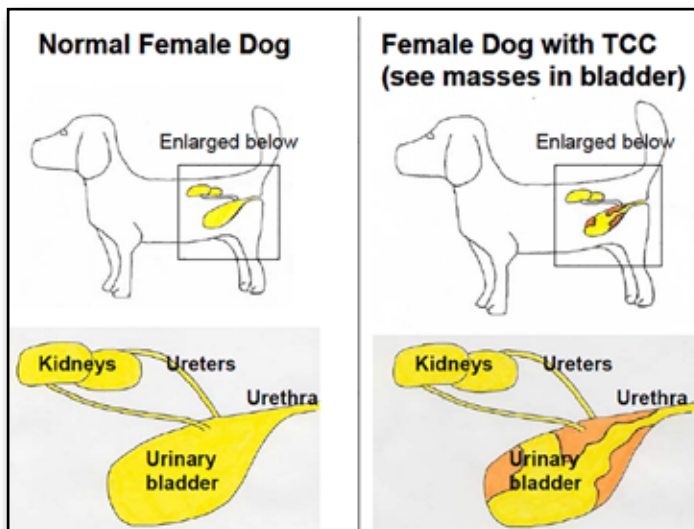
Compared to cancer in other locations in the body, bladder cancer is unusual, comprising approximately 2% of all cancers in the dog. With more than 70 million pet dogs in the United States, however, even unusual cancers like bladder cancer, are problems for thousands of dogs and their families.

What is bladder cancer?

The most common cancer of the dog urinary bladder is invasive transitional cell carcinoma (TCC) of intermediate to high grade. TCC is also called urothelial carcinoma. TCC is a malignant tumor that develops from the transitional epithelial cells that line the bladder. In dogs, this tumor invades into the deeper layers of the bladder wall including the muscle layers. As the cancer enlarges in the bladder, it can cause obstruction to the flow of urine from the kidneys to the bladder or from the bladder to the

outside of the body. Canine TCC also has the ability to spread to lymph nodes and to other organs in the body (lung, liver, others). TCC most frequently is found in the bladder, but can also develop in the kidneys, ureters, prostate, and urethra. In regards to human bladder cancer, most cases fall into two general categories: (1) lower grade, superficial tumors, and (2) higher grade, invasive tumors. It is fortunate that the majority of people with bladder cancer have the lower grade, superficial form of the disease, which typically does not spread

beyond the bladder. Dogs, on the other hand, most often develop the higher grade, invasive form of bladder cancer that can grow more quickly and can spread throughout the body.



Updated: April 2013

What causes TCC in dogs?

The exact cause of TCC in an individual dog is usually not known. In general, canine TCC results from a combination of several factors including genetic predisposition and environmental factors. A genetic predisposition is strongly suspected because TCC is more common in specific breeds of dogs. Scottish Terriers have an 18-20 fold higher risk of TCC than other dogs. Shetland Sheepdogs, Beagles, West Highland White Terriers, and Wire Hair Fox Terriers are 3 to 5 times more likely to develop TCC than other dogs. Dogs in related breeds may also have a higher risk of TCC, but this has not been studied yet. Environmental factors identified as risk factors in early studies have included pesticides and insecticides such as “old generation” flea dips. The greatest cause of TCC in humans is smoking. Further study is needed to determine the extent to which second hand smoke could contribute to TCC in dogs.

An association has been found between exposure to lawn herbicides and pesticides and the risk of TCC in Scottish Terriers. Investigators at the Purdue University School of Veterinary Medicine have published a case control study in Scottish Terriers to determine risk factors for the development of TCC. As discussed above, Scottish Terriers have an 18-20 times higher risk for developing TCC than dogs of other breeds. The study was performed to determine if exposure to certain types of

environmental chemicals would further increase the risk of TCC in this breed of dog. Environmental exposure histories were compared between 83 Scottish Terriers with TCC (cases) and 83 Scottish Terriers of approximately the same age with other health-related conditions (controls). A significantly increased risk of TCC was found for dogs exposed to lawns or gardens treated with herbicides and insecticides or herbicides alone. In fact dogs exposed to treated lawns were seven times more likely to develop TCC. These findings indicate that Scottish Terriers, as well as other dogs of high-risk breeds for TCC,

should be restricted from lawns treated with herbicides and pesticides. The risk of lawn chemicals to dogs in other breeds has not yet been determined.

(Continued on page 15)

What clinical signs or symptoms do dogs with TCC have?

Blood in the urine, straining to urinate, and making repeated frequent attempts to urinate are the most frequent signs of TCC in dogs. Pet owners must realize, however, that a urinary tract infection will cause these same symptoms, so the symptoms alone do not necessarily mean the dog has TCC. Less commonly, dogs with TCC can have lameness due to spread of the tumor into the bones or spread into the lungs and a paraneoplastic syndrome called hypertrophic osteopathy.

How is TCC diagnosed?

A diagnosis of TCC requires a tissue biopsy. Several other types of growths in the bladder, bladder infection, bladder stones, or bladder inflammation can cause similar symptoms as those in dogs with TCC. Some of these other conditions can also cause “masses” to be seen on radiographs or ultrasound, and these other conditions can cause abnormal cells in the urine, which can be mistaken for TCC. Therefore, the diagnosis of TCC requires a tissue biopsy. This is important because the treatment and prognosis depend entirely on exactly what is wrong with the bladder. A tissue biopsy can be obtained by surgery, cystoscopy (insertion of a fiberoptic scope into the bladder and biopsy through the scope), or in some cases with a urinary catheter.

What evaluation is needed for a dog with TCC?

Once a diagnosis of TCC is made, it is important to determine the extent of the tumor, i.e. to perform “tumor staging”. Tumor staging is performed to determine the best way to treat the cancer, to provide some information regarding prognosis, and to establish a baseline set of tumor measurements in order to determine if subsequent treatment is being successful. Tumor staging for TCC includes radiographs (“x-rays”) of the thorax to look for lung metastasis, radiographs and ultrasound (or CT scan) of the abdomen to look for metastasis in the abdomen and to assess any changes in the kidneys that result from obstructed urine flow, and imaging of the bladder to determine the exact location and size of the tumor within the bladder (see Figure 1). This information is needed to best plan how to treat the cancer. Also, these tests are repeated during treatment to know if the treatment is being effective.

How is TCC treated?

For dogs with TCC that has not spread beyond the bladder, surgical excision could be considered. In order to surgically excise the tumor, however, it needs to be located away from the neck (also called the trigone) of the bladder and the urethra. Several vital structures in the neck of the bladder (junction with ureters and urethra, urethral sphincter) usually prevent surgical

excision of tumors in this location. This is especially true because malignant tumors, like TCC, need to be removed with a “margin” of normal tissue around the tumor. This “margin” often contains microscopic tumor cells that, left behind, would result in cancer regrowth. In addition, most canine TCCs invade down into the bladder wall and therefore, surgical excision requires removal of a complete full thickness section of bladder wall. [Note: in humans with superficial, low grade cancer, this is not typically the case.] Because most canine TCCs are invasive into the bladder wall and located in the neck of the bladder, surgical removal is usually not possible. It has not yet been completely determined what benefit would occur from removing part of the tumor (in dogs in which the entire tumor cannot be removed).

If surgery is not possible, what other treatment options are available? Radiation therapy has been used to successfully control TCC growth in the bladder in dogs. Unfortunately, radiation given in traditional doses when applied to the bladder can lead to harmful complications including a scarred, shrunken bladder, and irritation to surrounding organs. One of the challenges in applying radiation to the bladder is that the bladder can move or flop within the abdomen and take on a different shape depending on how much urine is in the bladder and if structures next to the bladder such as the bowel are pushing in on the bladder. To use radiation therapy successfully in canine TCC, different treatment schemes need to be developed. Studies are underway, and results may help determine if radiation will have a role in treating TCC in dogs.

The vast majority of dogs with TCC are treated with medical therapy, i.e. with drugs. Three different drug protocols are used most often in the standard care for dogs with TCC. The first treatment protocol is to give a drug called piroxicam, or a piroxicam-like drug by itself. Piroxicam is a type of drug called a nonsteroidal antiinflammatory drug or “NSAID”. NSAIDs block the cyclooxygenase (cox) enzyme, and are also referred to as “cox inhibitors”. Cox inhibitors include piroxicam, aspirin, ibuprofen, Previcox, Deramaxx, Rimadyl, and others. There is an interesting history behind the use of cox inhibitors for the treatment of TCC in dogs. Veterinarians in the Purdue Comparative Oncology Program and a veterinarian colleague (Dr. T Needham, Wilmington N.C.) became interested in piroxicam several years ago when it was being used for pain relief in dogs with cancer, and unexpected remissions were noted. Two of the first dogs treated (one with metastatic carcinoma, one with undifferentiated sarcoma) had advanced cancer, and these dogs had remission of their cancer when receiving piroxicam, but no other treatment. This has led to numerous studies of piroxicam in animals with cancer at Purdue. In 62 dogs with TCC treated with piroxicam, the tumor went into complete remission in 2 dogs, decreased in size by > 50% in 9 dogs, remained “stable” in size (<50% change) in 35 dogs,

(Continued on page 16)

and increased in size by > 50% in 16 dogs. Although remission is certainly the preferred treatment outcome, “stable disease” is also considered a beneficial response when the dog is feeling well and enjoying life. In that scenario, the cancer is “managed” as a chronic disease, and the dog lives with it. The median (“average”) survival of the dogs treated with piroxicam was 195 days.

The second treatment protocol used as a standard treatment for dogs with TCC is to combine piroxicam with an intravenous chemotherapy drug called mitoxantrone. In a study performed by the Veterinary Cooperative Oncology Group, this combination treatment resulted in a remission rate of approximately 35%. In addition to dogs that had remission, 46% of the dogs also had “stable disease” where the cancer did not grow for a period of time. “Average” survival times with mitoxantrone/piroxicam have been in the 250-300 day range. Some dogs live much longer than this, while others do not live this long.

A third treatment that has gained attention in recent years is to use a drug called vinblastine to treat TCC. Vinblastine is a chemotherapy drug that is given intravenously at 2 week intervals in dogs with TCC. Although vinblastine has been used for decades to treat other cancers in dogs, it has only recently been appreciated for its benefit in dogs with TCC. In fact, an “accidental” discovery in cell culture studies revealed the benefit of this drug against TCC. Vinblastine resulted in remission in 35% of dogs, and stable disease (cancer control, but not shrink) in 50% of dogs in a study at Purdue University. A follow up study is addressing the question of whether piroxicam will make vinblastine work better, as is the case with some other chemotherapies.

Results of another treatment study are expected to be published in the next 6 months that define another treatment option for dogs with TCC, that is “metronomic” chemotherapy. The term metronomic chemotherapy is used to describe the frequent (typically daily), low dose, oral administration of chemotherapy. In order to be given daily, the drug doses are quite low. In fact at the doses used, the chemotherapy is probably not having direct cytotoxic activity, i.e. not directly killing the cancer cells. This type of chemotherapy schedule was developed with the goal to block the formation of new blood vessels in the cancer, that is to have an “anti-angiogenic” effect. If the cancer cannot gain access to new blood vessels, it cannot grow. Recently, other mechanisms of cancer control have also been proposed for this metronomic treatment approach. The expected outcome of metronomic chemotherapy is that the cancer will stop growing for a period of time (ideally for many months or more). The cancer is not expected to shrink, but to stabilize in growth. Briefly, in a study at Purdue University, a series of 31 dogs with TCC were treated with low dose oral chlorambucil (also

called leukeran). In the study, 1 dog had remission, and 20 dogs had stable disease, for a cancer control rate of 70%. This was encouraging since the cancer in all but 2 of the dogs had already developed resistance to other therapies. The median (“average”) length of life from the start of chlorambucil to death was 7 months, and this extended life was after other therapies had stopped working. The therapy was well tolerated with toxicity being very uncommon. The veterinarian can discuss with the pet owner whether “cancer control”, rather than cancer shrink is an appropriate goal for an individual dog.

Regardless of the treatment pursued, the typical plan followed in most dogs with TCC at Purdue University is to measure the extent of the tumor before treatment, and then to remeasure the tumor after 4-8 weeks of treatment (depending on the drug used). Various tests are also used to detect any side effects. If the tumor is shrinking or remaining stable in size after 4-8 weeks, and the dog is feeling well on that therapy, then the same treatment is continued. If the cancer is not responding, i.e. if it is growing, or if the dog does not feel well on that particular treatment, then a different treatment is initiated. After each 4- 8 weeks of treatment the tumor is remeasured to confirm the treatment is still being beneficial.

Beyond the options discussed above, there are other treatments that can also help dogs with TCC. One of the more active types of TCC treatment in humans is “platinum” chemotherapy, primarily consisting of the drugs cisplatin and carboplatin. These drugs have had considerable antitumor activity against canine TCC as well. Cisplatin, however, is not used in dogs very commonly anymore because of risk of damage to the kidneys. Carboplatin is used, but needs to be dosed carefully to limit the risk of side effects. Carboplatin may have a new role when combined with a new type of drug – a demethylating agent. Stay tuned for results of ongoing research.

Pet owners that know humans with bladder cancer often ask why intravesical therapy is not done more often in dogs with TCC. Intravesical therapy, which refers to placing anticancer drugs directly into the bladder through a urinary catheter, is a mainstay in the treatment of humans with superficial TCC. The drug is expected to stay in the bladder where high concentrations can come in direct contact with the cancer. Initially, it was not known if intravesical therapy would be of benefit in dogs because TCC in dogs would be deeper in the bladder wall, and tumor masses would often be larger than those treated in humans. This would limit the access of the drug to the tumor. A clinical trial of intravesical therapy (specifically intravesical mitomycin C) in 12 dogs with TCC at Purdue University revealed two important findings. The first finding was that the antitumor effects were encouraging, consisting of partial remission in 5 dogs and stable disease in 7 dogs. Unfortunately,

(Continued on page 17)

the second important finding was that in 2 dogs, the drug appeared to pass from the bladder into the blood stream and then throughout the body. These dogs had toxicity similar to what would occur with high dose intravenous chemotherapy. Although both dogs recovered, if a larger amount of drug were to be absorbed into the blood stream, it could cause more serious and life threatening side effects. For this reason, intravesical mitomycin C therapy is not typically given to dogs if there are other treatment options available.

In order to improve the outlook for dogs and human with invasive bladder cancer, the Purdue Comparative Oncology Program is conducting clinical trials in dogs with TCC. Dogs that take advantage of the clinical trials as well as standard care over the course of their cancer, can have longer survival, typically well beyond a year for many dogs. Clinical trials in dogs are similar to clinical trials in humans. The dogs live at home with

their families, and come into the Purdue University Veterinary Teaching Hospital periodically for evaluation and treatment. Quality of life for the dogs is the highest priority, so treatments evaluated in clinical trials are selected with the goal of having antitumor effects with low risk of serious side effects. The advantages for a dog participating in a clinical trial are that the dog is receiving treatment that is expected to be as effective or more effective than standard therapies, the dog is helping veterinarians learn important information that is expected to help other dogs and even humans with bladder cancer, and the dog is receiving some "hope" if standard therapy has failed. In some instances, participating in a treatment trial is less expensive than other treatments.

Many pet owners have observed humans undergoing chemotherapy and are concerned that some of the serious side effects of chemotherapy in humans will

also be observed in pet dogs. Fortunately, most dogs treated with chemotherapy, experience much less toxicity than humans receiving chemotherapy. The side effects of chemotherapy are considered acceptable in most dogs. Treatment protocols are selected with the goal of maintaining or improving quality of life, at the same time the cancer is attacked. The pet owner should discuss the possible benefits and risk of specific medications that their dog may receive with the attending veterinarian. Cox inhibitors like piroxicam have few side effects. In some dogs (<20%), however, piroxicam will irritate the stomach or intestine. Therefore, if a dog on piroxicam has loss of appetite, vomiting, or dark tarry-looking stools, it is safest to stop the piroxicam and consult the veterinarian before starting the medication again. The new cox inhibitors, selective cox-2 inhibitors, are not expected to cause stomach irritation as frequently as piroxicam does.

(Part 2 to be continued in the Fall Issue)

Getting to Know the Foundation Board

Pamela G. Whiting, DVM WFA Board Member



My first Westie (1964) came from Ms. FMC Cook of Famecheck Kennels and later another from Mrs. DM Dennis of Branston Kennels. I was blessed to have my first experience with Westies to come from the famous English lines of

the past. This was also my introduction to the world of dog shows (East Coast). My dogs retired when I went off to college (William and Mary), veterinary school (UGa), internship (AMC, NYC), residency

(UCD), NIH postdoc..... Until I was ready to repopulate my life with Westies, (As a veterinarian, adopting the 3 legged kitten, the abused German Shepherd, the paralyzed HBC kitten, the abandoned Labrador, etc.) has been an occupational hazard...So the Westies have often had to share space.

My early research and publications were in surgical intervention of vascular diseases of the liver, especially portosystemic shunts. When I left surgical research, I managed several critical care/emergency clinics for several years. For the past 22 years I have had a small veterinary clinic in Windsor, California.

I have shown and bred Westies under the Wyndbrae prefix. Sherry Byrd, Winnie Noble and I have formed a close friendship over Mac, GCh Ch Wyndbrae's Maclaren. We are very proud of him and his winning accomplishments and unbeatable

personality. Despite limited breeding we have celebrated our 30th champion and are enjoying new puppies in the ring.

Between my early Westies and my current Westies, I had purchased a pet Westie who was my academic companion. In 1996 I lost Mousse to pulmonary fibrosis; this unrelenting disease was devastating and seemed "out of the blue" in its serious and unusual presentation. Then in 1999 Brendan Corcoran published a review of 29 similar cases in West Highland White Terriers and our fight was on to understand and hopefully triumph over this horrible disease. With each new case of pulmonary fibrosis that I see I feel catapulted in our struggle to understand this disease and find answers in treatment and hopefully prevention. I hope that my interest and haunted desire to beat this cruel disease will be a benefit to the Westie Foundation.